



Osteonecrosi del Mascellari (ONJ): Prevenzione, Diagnosi, Trattamento UPDATE 2009

Segreteria Scientifica:
Vittorio Fusco - Alessandria
Giuseppina Campisi - Palermo
Segreteria Organizzativa e ECM
M & B s.n.c.
Via Cialdini, 41 - 10138 Torino
tel. 011.433.23.36
cell. 334.57.71.646 - 348.09.60.100 -
347.25.11.673
e-mail: info@mb-meeting.com
sito internet: www.mb-meeting.com

Il **Centro Documentazione Osteonecrosi**
(tel 0131206753 - osteonecrosi@ospedale.al.it)
e' supportato da



Si ringrazia per il contributo incondizionato
Hospira
Novartis Oncology



23 Giugno 2009

Associazione Cultura e Sviluppo
Piazza F. De Andre' 76 - Alessandria

Presidenti:
Guido Bottero, Alessandro Levis

Coordinatori Scientifici:
Vittorio Fusco - Anna Baraldi

Con il Patrocinio di :



AI AIL - ONIUS
Alessandria




Lega Italiana per la Lotta
contro i Tumori
Sez. di Alessandria



Associazione
C. Ciliberto
Novi Ligure

-SIE - Societa' Italiana Ematologia
-Ordine dei Medici Chirurghi ed
Odontoiatri della Prov. di Alessandria



FONDAZIONE IRCCS
ISTITUTO NAZIONALE
DEI TUMORI



Sotto l'alto patrocinio



Presidenza del Consiglio dei Ministri

Carla Ripamonti, Massimo Maniezzo, Enrico Cislighi



Poster #
194

Medical Ozone Oil Suspension Applications Heal Osteonecrosis of the Jaw (ONJ) in Patients Treated with Bisphosphonates (BPs): Preliminary Results of a Single Institution Protocol

Ripamonti C.¹, Maniezzo M.², Ghiringhelli R.³, Fagnoni E.³, Campa T.³, Mariani L.⁴ and Cislaghi E.⁵

¹Palliative Care Unit, IRCCS Foundation, National Cancer Institute of Milan, Milan, Italy, 20133; ²Dental Team, IRCCS Foundation, National Cancer Institute of Milan, Milan, Italy; ³Dental Team, Sanipian, Varese, Italy and ⁴Medical Statistic and Biometry Unit, IRCCS Foundation, National Cancer Institute of Milan, Milan, Italy

Abstract

ONJ is an uncommon condition mainly reported in oncological patients receiving BPs. We previously demonstrated that routine application of preventive measures before and during BP therapy, lead to a reduction of 70% in the incidence of ONJ (Ripamonti 2009). However, a strategy is still needed in order to treat patients who develop ONJ. Recently, we investigated the effect of the localized application of a medical ozone oil suspension (O₃ oil) on ONJ lesions. Ten cancer patients (seven with breast cancer), with active ONJ lesions < 2.5 cm, in good clinical condition, were treated with antibiotic therapy 10 days prior the initiation of the treatment consisting in the repeated application of O₃ oil on ONJ lesions, at 3 days interval, for a maximum of 10 applications. Herein we report the results obtained in the first 10 patients enrolled with a follow up of at least 6 months, while the second stage of the trial, according to the Simon two-stage design, is currently ongoing to better estimate the response rate.

Patients with breast cancer (n=7), prostate cancer (n=1), NHL (n=1) and multiple myeloma (n=1) had previously received NBPs treatment in the absence of radiologically irreversible metastases. The mean time between the diagnosis of ONJ and the first O₃ oil application was 360 days. All the patients treated showed complete responses, in terms of radiological lesion disappearance with complete reconstitution of oral tissue, which was achieved with 3 applications in 3 patients, 4 applications in 4 patients and 10 applications in 3 patients (the mean recovery time was 26 days). 8/10 patients developed spontaneous sequestrum with expulsion of the necrotic bone.

According to these results few application of medical ozone oil suspension can rapidly lead to complete ONJ resolution. Further cases are required to confirm these data, which seem to indicate that ONJ is not only a preventable but also a manageable and curable condition.

Introduction

- Bisphosphonates (BPs) are well established and a recommended therapy to reduce the frequency and severity of skeletal related events (SREs) due to bone metastases in patients of solid tumors or multiple myeloma.¹
- Osteonecrosis of the jaw (ONJ) is an uncommon (<1%) adverse event which has been reported in patients receiving complex cancer treatment regimens, including BPs.²
- The exact etiology of ONJ is still unclear, however putative risk factors include concurrent disease, tooth extractions or invasive dental surgery during the course of BP therapy, duration of administration and type of BP, poor oral hygiene and use of concomitant cancer drugs such as chemotherapy, tralidomide, and corticosteroids.³
- Prevention and therapeutic management of ONJ is essential in view of the considerable benefits of BPs, in the prevention of bone metastases-related SREs.
- The application of simple preventive measures such as proper dental hygiene, avoidance of dental procedures during BP treatment, and frequent dental examinations have been shown to effectively reduce ONJ incidence up to 70%.⁴
- There are however few current options to treat ONJ, and recent recommendations for the treatment of ONJ include prophylactic antibiotics, the use of oral antimicrobial rinses, and debridement (Table 5).

Table 1. Staging and Treatment of Osteonecrosis of the Jaw (AAOMS 2009)⁵

ONJ stage	Treatment recommendations
All risk: No apparent necrotic bone in patients who have been treated with either oral or intravenous bisphosphonates	No treatment indicated Patient education
Stage 0: No clinical evidence of necrotic bone, but non-specific clinical findings and symptoms	Systemic management, including the use of pain medication and antibiotics
Stage 1: Exposed/necrotic bone in patients who are asymptomatic and have no evidence of infection	Antibacterial mouth rinse Clinical follow-up on a quarterly basis Patient education and review of indications for continued bisphosphonate therapy
Stage 2: Exposed/necrotic bone associated with infection as evidenced by pain and erythema in the region of the exposed bone with or without purulent drainage	Symptomatic treatment with systemic antibiotics Oral antibacterial mouth rinse Pain control Superficial debridement to relieve soft tissue irritation
Stage 3: Exposed/necrotic bone in patients with pain, infection, and one or more of the following: pathologic fracture, extraoral fistula, or osteolysis extending to the inferior border	Antibacterial mouth rinse Antibiotic therapy Surgical debridement/resection for longer term cessation of infection and pain

⁵From: American Association of Oral and Maxillofacial Surgeons-Position Paper on Bisphosphonate-Related Osteonecrosis of the Jaw-2009 Update
AAOMS: American Association of Oral and Maxillofacial Surgeons

- Ozone therapy (O₃) has previously been shown to enhance the benefits of surgical and pharmacologic treatments of ONJ when administered before and after treatment procedures.⁶
- The present study assesses the therapeutic potential of the localized application of medical O₃ oil suspension for the treatment of ONJ lesions following prior antibiotic treatment.

Methods

Eligibility criteria

- Cancer patients who previously received N-BPs treatment in the absence of odontologic preventive measures and who developed stage 2 (AAOMS 2009 guidelines)⁵ ONJ lesions were included in the study.

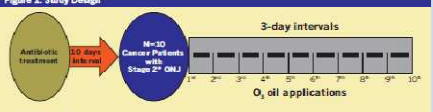
Diagnosis of ONJ

- ONJ was defined by the presence of exposed bone in the maxillofacial region with no evidence of healing after 6 weeks with appropriate dental care.
- A differential diagnostic methodology was followed to distinguish ONJ lesions from metastatic disease of the jaw or osteoradionecrosis.⁷

Procedure

- Patients were treated with antibiotic therapy (amoxicillin [Zithromax][®] 500 mg/day for 9 days) 10 days prior to the initiation of the investigational treatment.
- The experimental treatment consisted of 10 applications of O₃ oil on the ONJ lesions, at 3 days interval (Figure 1).

Figure 1. Study Design



- This investigation is based on a Simon stage-two design and the present report discusses the findings from the preliminary phase in which 10 patients had been enrolled with a follow-up of at least 6 months.
- Patient number was calculated assuming a probability of 0% of null and alternative hypotheses of 8% and 25%, respectively, and a probability of type I and II errors of 10%.

Primary end-point

- The goal of the study was to evaluate the level of healing response, and radiological lesion disappearance with complete reconstitution of oral tissue.

Results

- A total of 10 patients: breast cancer (n=7), prostate cancer (n=1), non-Hodgkin lymphoma (n=1) and multiple myeloma (n=1) were enrolled in the study.
- The median time between the diagnosis of ONJ and the first O₃ oil application was 360 days.
- Patient demographics and baseline characteristics (Table 2).

	Patients (N=10)
Age range, years	46-74
Sex, n	
Female	8
Male	2
Primary Tumor, n	
Breast	7
Prostate	1
Multiple Myeloma	1
Non-Hodgkin's Lymphoma	1
Mean time from ONJ diagnosis to Ozone oil therapy	360

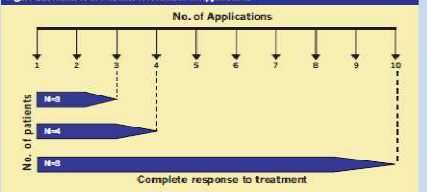
Results (Efficacy)

- All the patients treated showed complete response, in terms of radiological lesion disappearance with complete reconstitution of oral tissue. The mean recovery time was 26 days. Response before, during and after completion of treatment are displayed in (Figure 2A).
- Seventy percent of the patients experienced a complete response after 4 applications (Figure 2B).
- Eight out of 10 patients developed spontaneous sequestrum with expulsion of the necrotic bone.

Figure 2A. Response to O₃ Oil Treatment

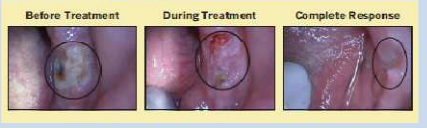

Figure 2B. Number of Patients vs. Number of Applications



Conclusions

- The current study demonstrates that O₃ oil may have a useful clinical application and could be considered as a possible strategy for managing and treating ONJ. The results of this study demonstrated that the application of medical ozone oil suspension rapidly and completely resolved ONJ in all the patients treated. However, these results should be considered as preliminary due to the small sample size of this study and warrants further investigation in a larger patient population.
- Previous investigators have demonstrated that the incidence of ONJ can be drastically reduced with the introduction of optimal preventive measures before and during BP treatment.⁴
- Emerging promising therapeutic options such as O₃ oil indicate that ONJ can also be treated, enabling patients to recover and heal from this debilitating condition.
- Cancer patients and clinicians should weigh the considerable benefits of BPs towards management of skeletal health as opposed to the possible risks posed by ONJ which is preventable and also manageable.

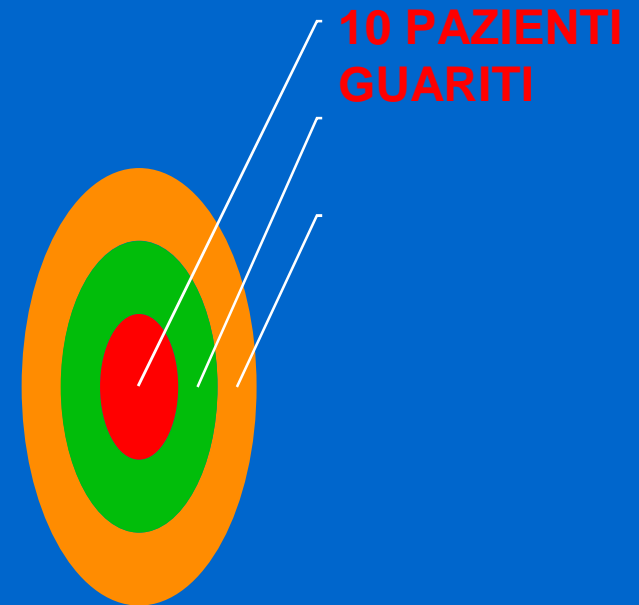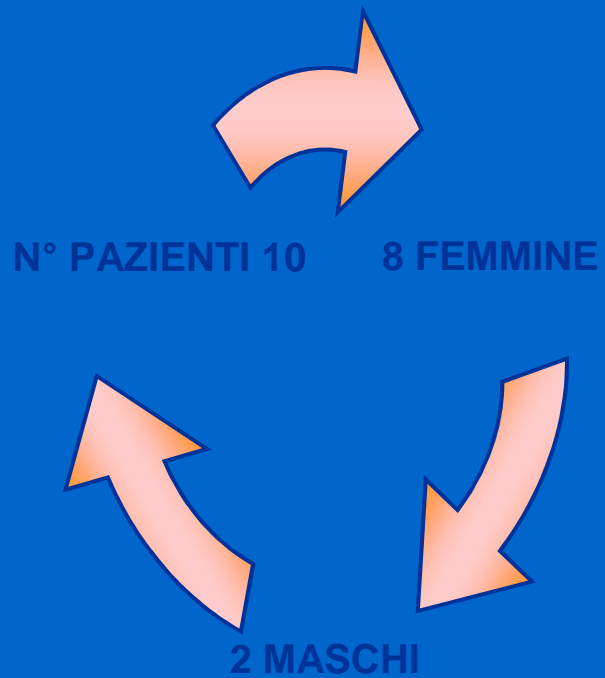
References

- Adami M et al. *Ann Oncol*. 2008; 19 (3): 420-432.
- Helfrich M et al. *J Bone Mineral Density* 2008; 23 (8): 826-836.
- Woo SB, Mathisen DN, Palmer JR. *Ann Intern Med*. 2006; 144: 753-761.
- American Association of Oral and Maxillofacial Surgeons. Position Paper on Bisphosphonate-Related Osteonecrosis of the Jaw-2009 Update http://www.aaoms.org/aaoms_position_paper_on_bisphosphonate.pdf
- Ripamonti C et al. *Ann Oncol*. 2009; 20 (3): 137-145.
- Aglio G et al. *J Cardiovascular Surgery*. 2007; 18 (5): 1068-1073.
- Reichert et al. *Haematologica* 2007; 92: 1286-1290.
- Wertzman R et al. *Crit Rev Oncol Metast*. 2007; 62: 148-152.
- Dimitrakopoul et al. *Ann Oncol* 2009; 20 (11): 117-120.

Presented at 11th St. Gallens BC Conference, March 11-14, 2009, St. Gallen, Switzerland

-
-
-

Protocollo ozonoterapia



Protocollo ozonoterapia

- Il Goal dello studio era di valutare le risposte complete e la scomparsa della lesione radiologica con completa ricostruzione del tessuto della cavità orale

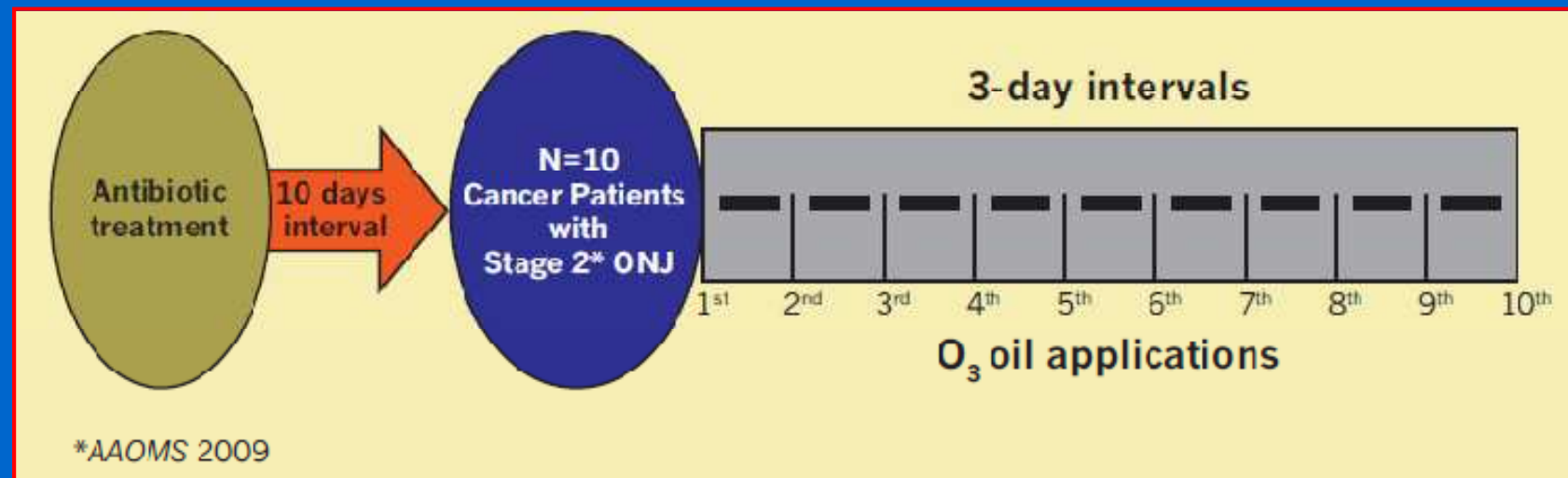
Numero di pazienti totale: 10

N= 7 tumore alla mammella

N= 1 tumore alla prostata

N= 1 linfoma non-Hodgking

N= 1 mieloma multiplo



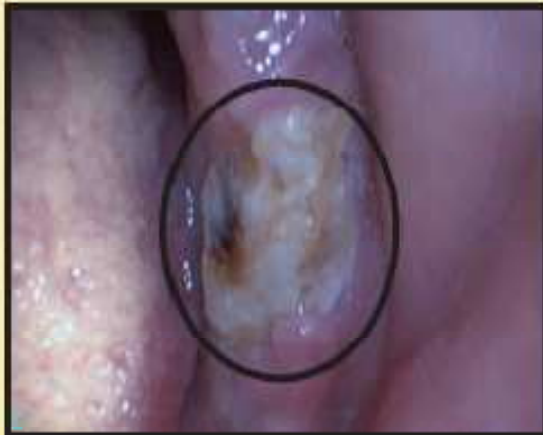Risposta (Efficacia)

- Tutti i pazienti trattati mostrano una risposta completa in termini di scomparsa della lesione (comprovata radiologicamente) e completa ricostruzione dei tessuti del cavo orale
- Il tempo medio di guarigione era di 26 giorni
- Il 70% dei pazienti ha una guarigione completa dopo 4 applicazioni
- 8 su 10 pazienti sviluppano sequestro ed espulsione dell'osso necrotico

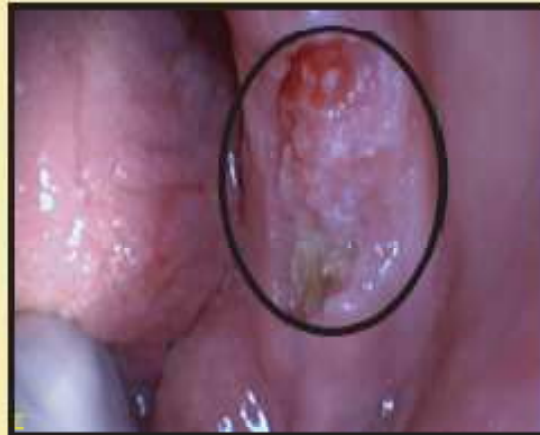-
-
-

Risposta all'ozono terapia:

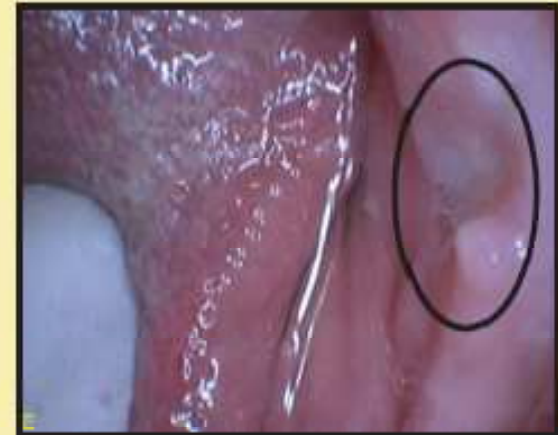Before Treatment



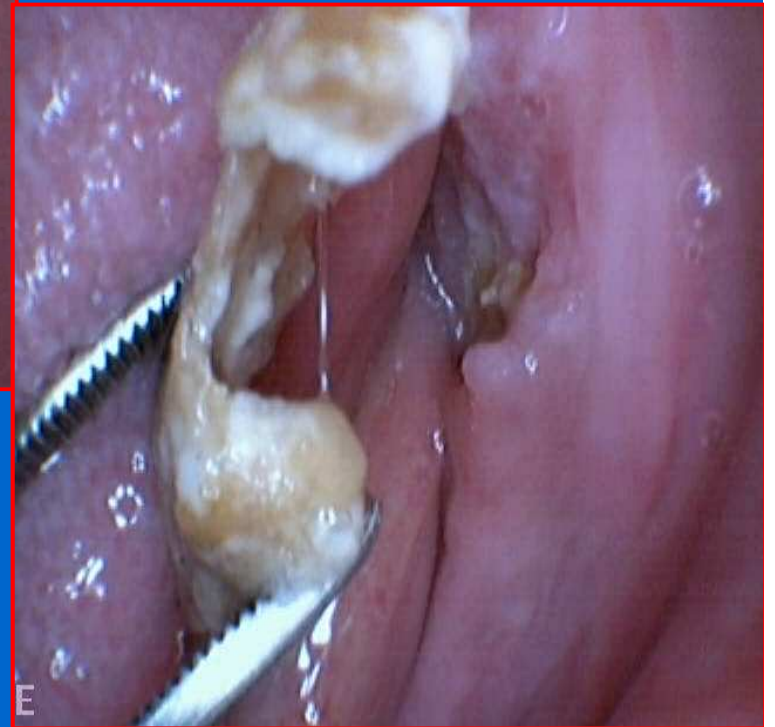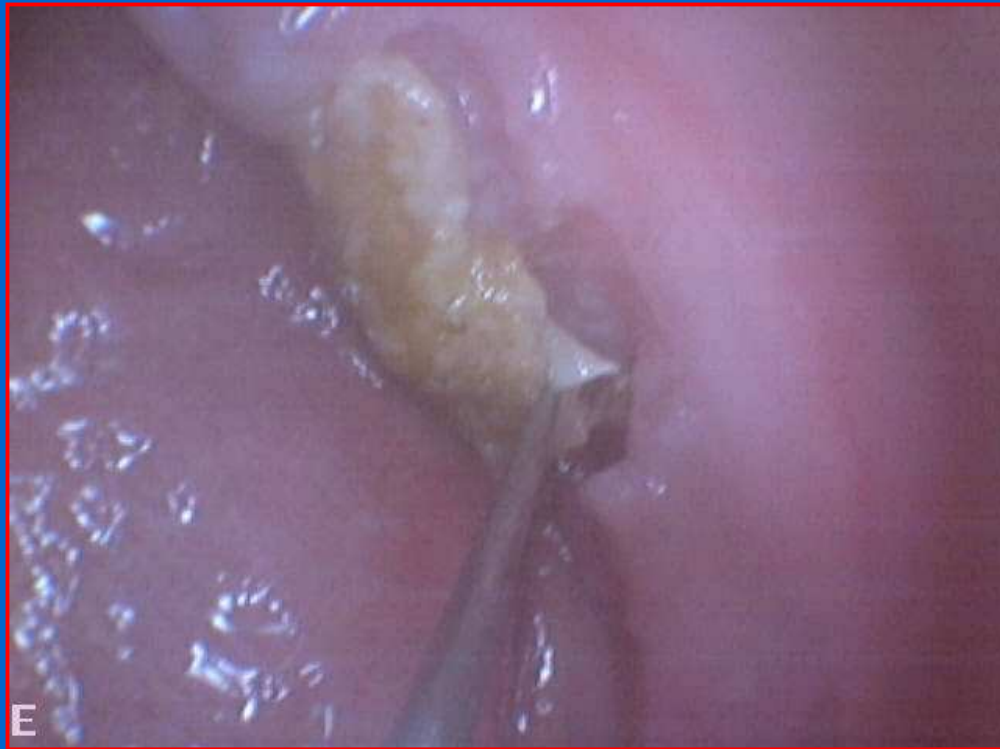During Treatment



Complete Response



-
-
-



-

-

-

-

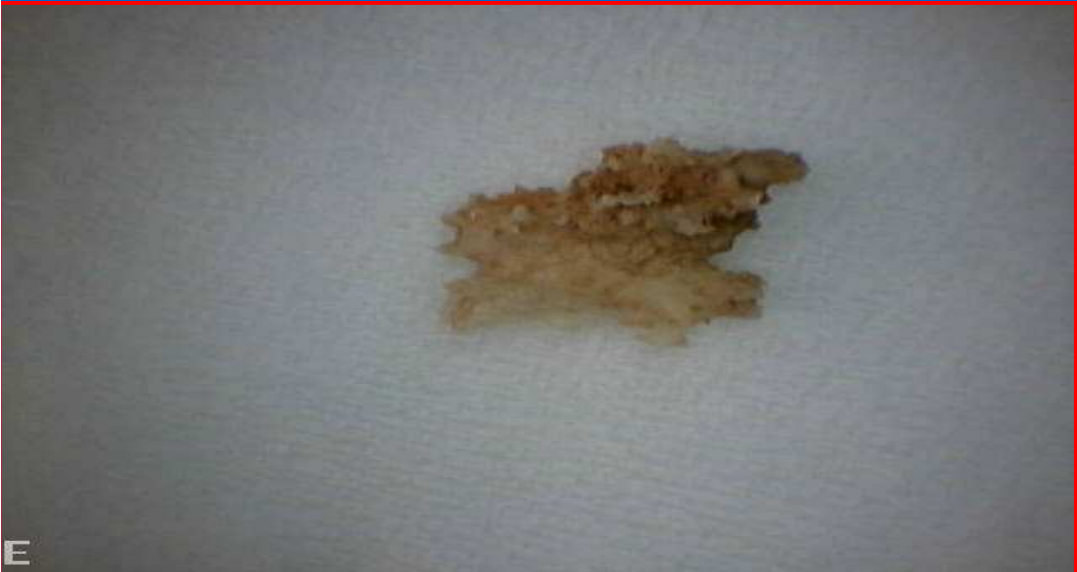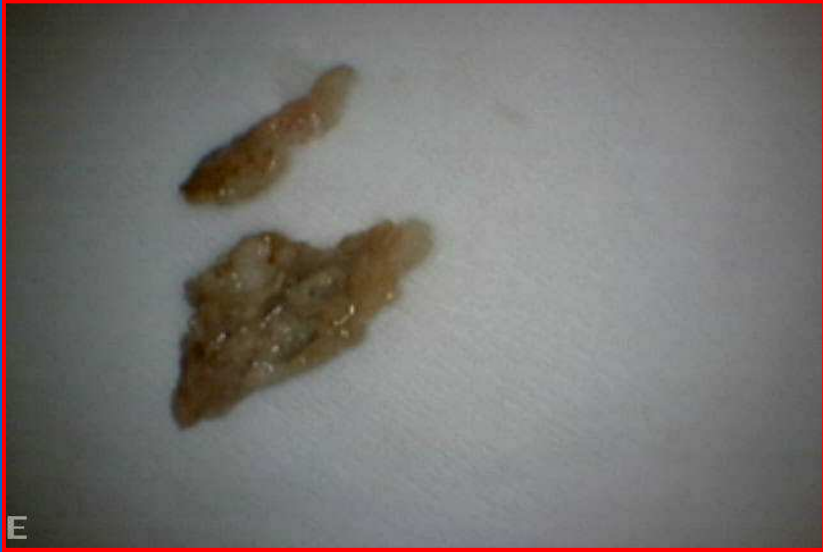-

-

-

-

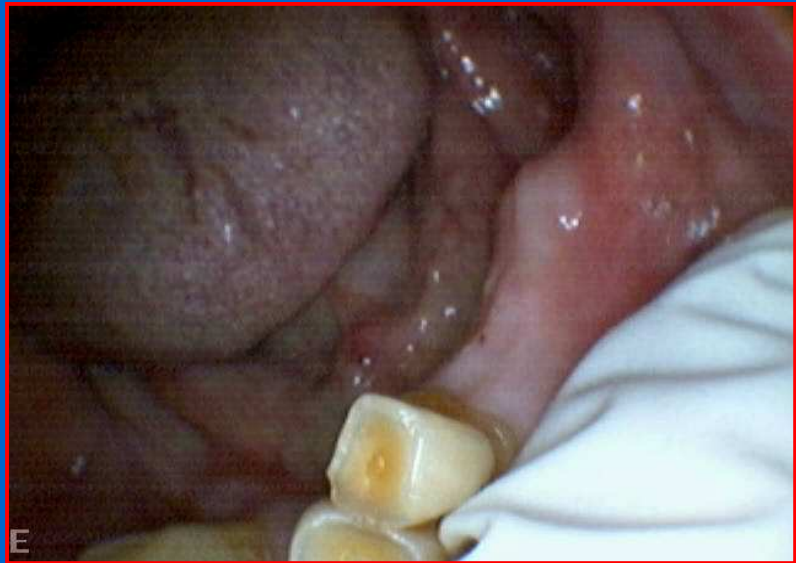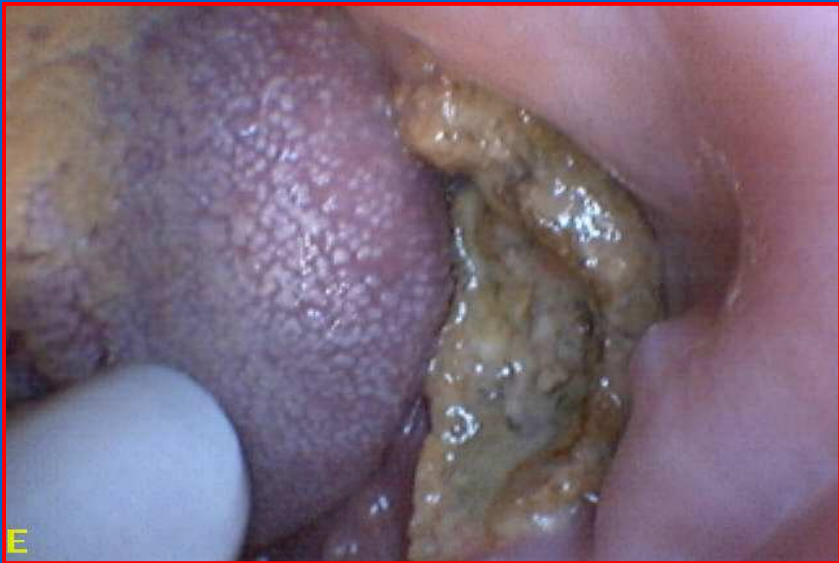-
-
-



-
-
-
-
-
-
-

-
-
-

[Redacted text block]

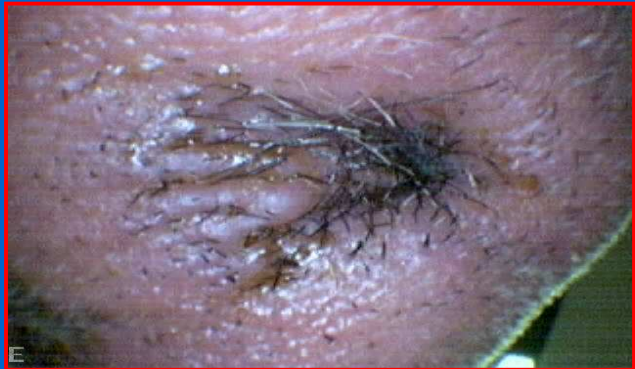
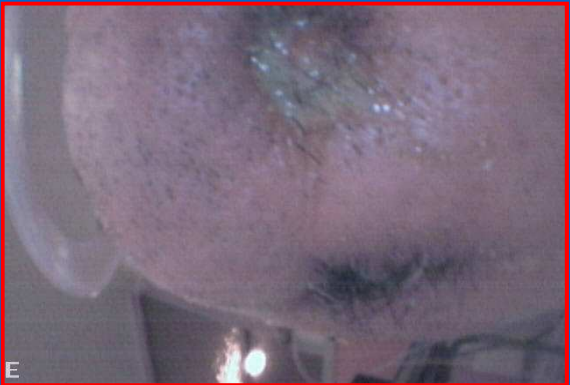
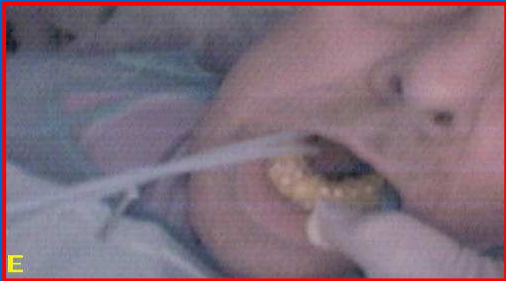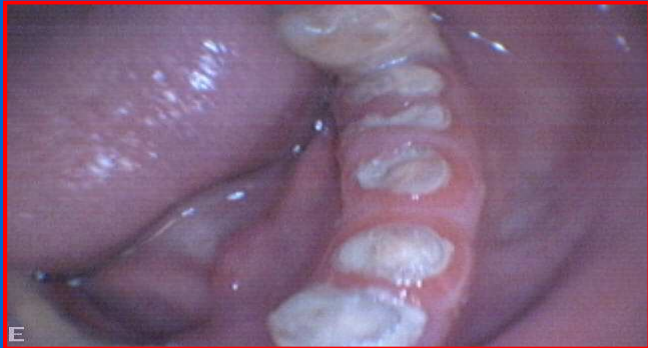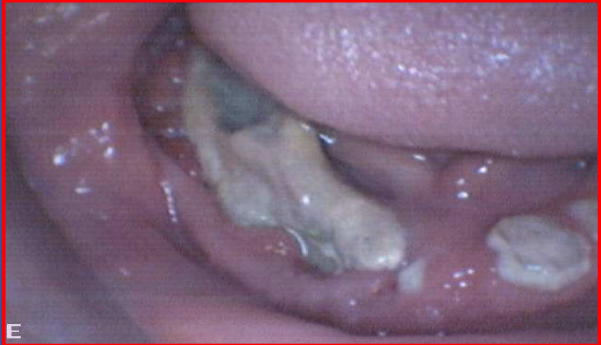[Redacted text block]

-
-
-
-
-
-
-
-

-
-
-

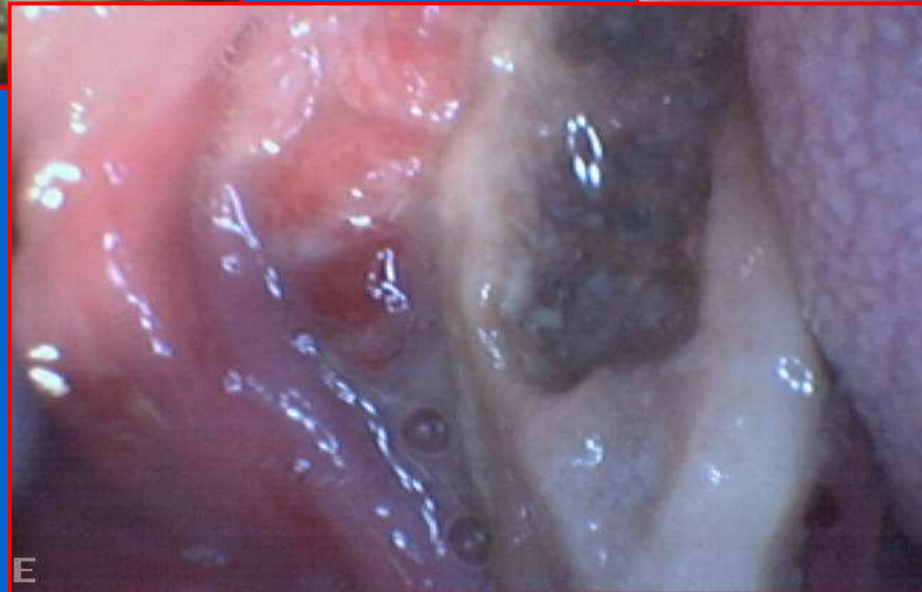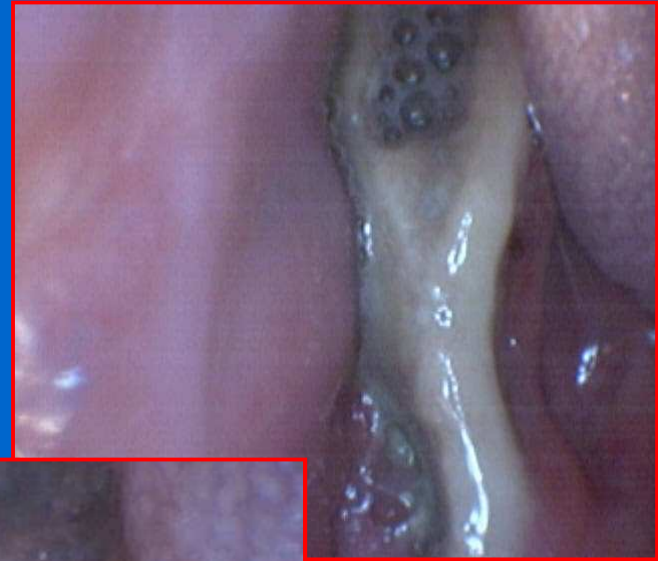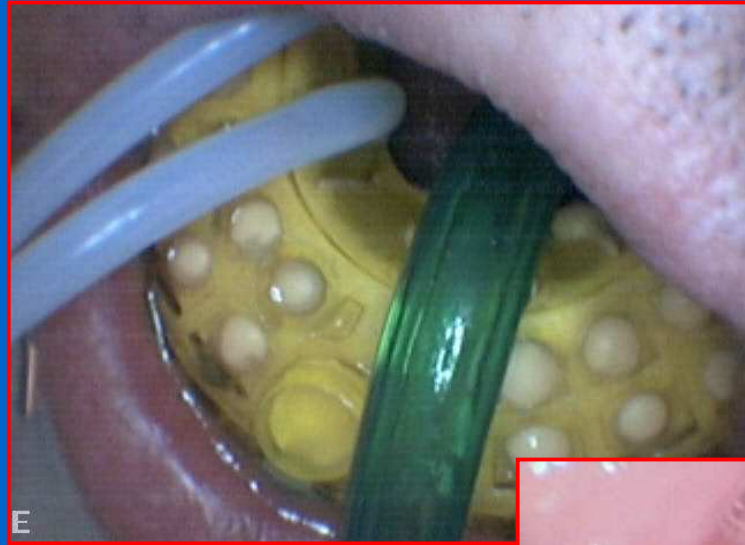
[Redacted text bar]



[Redacted text bar]

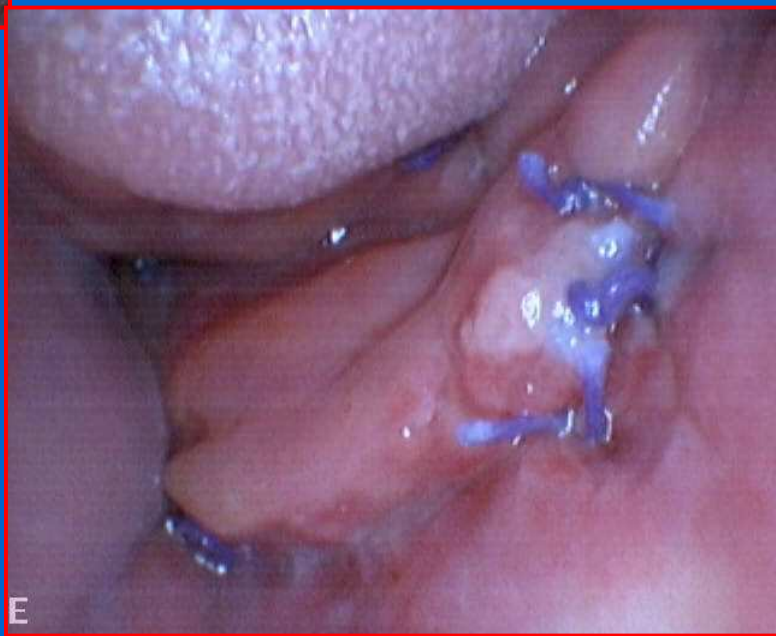-
-
-
-
-
-
-
-

-
-
-



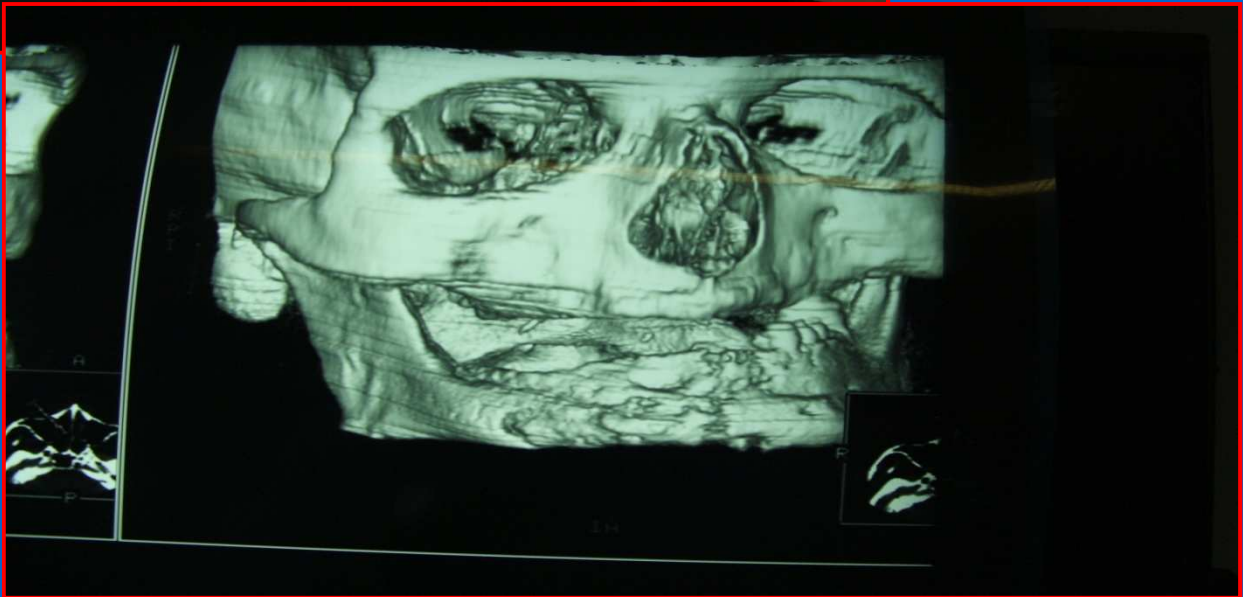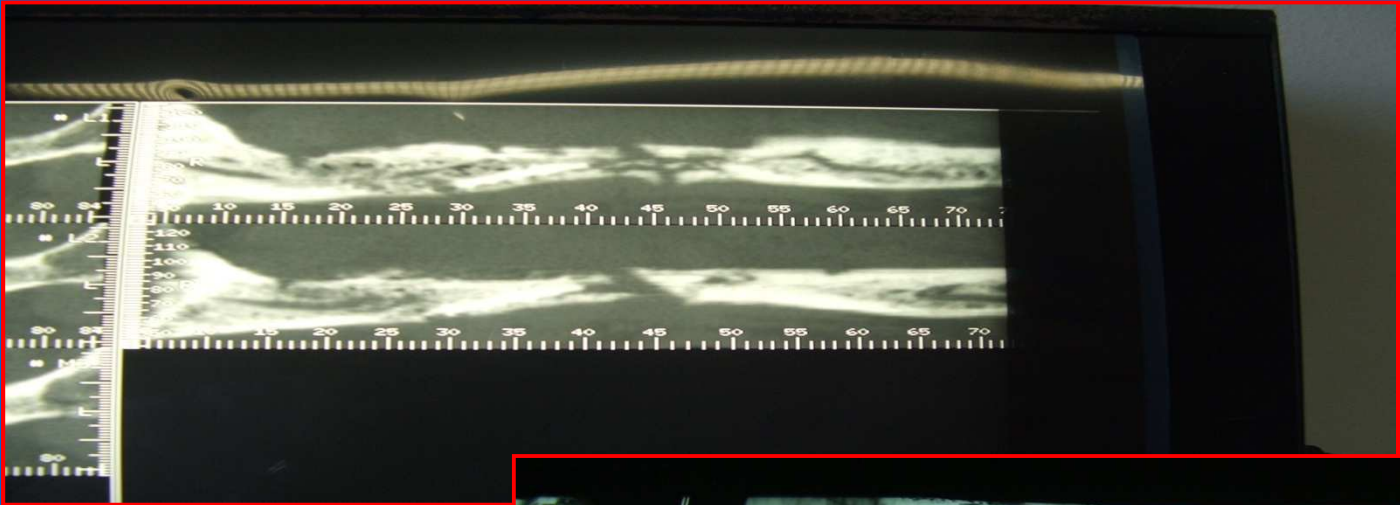
-
-
-
-
-
-
-
-

-
-
-



-
-
-
-
-
-
-
-

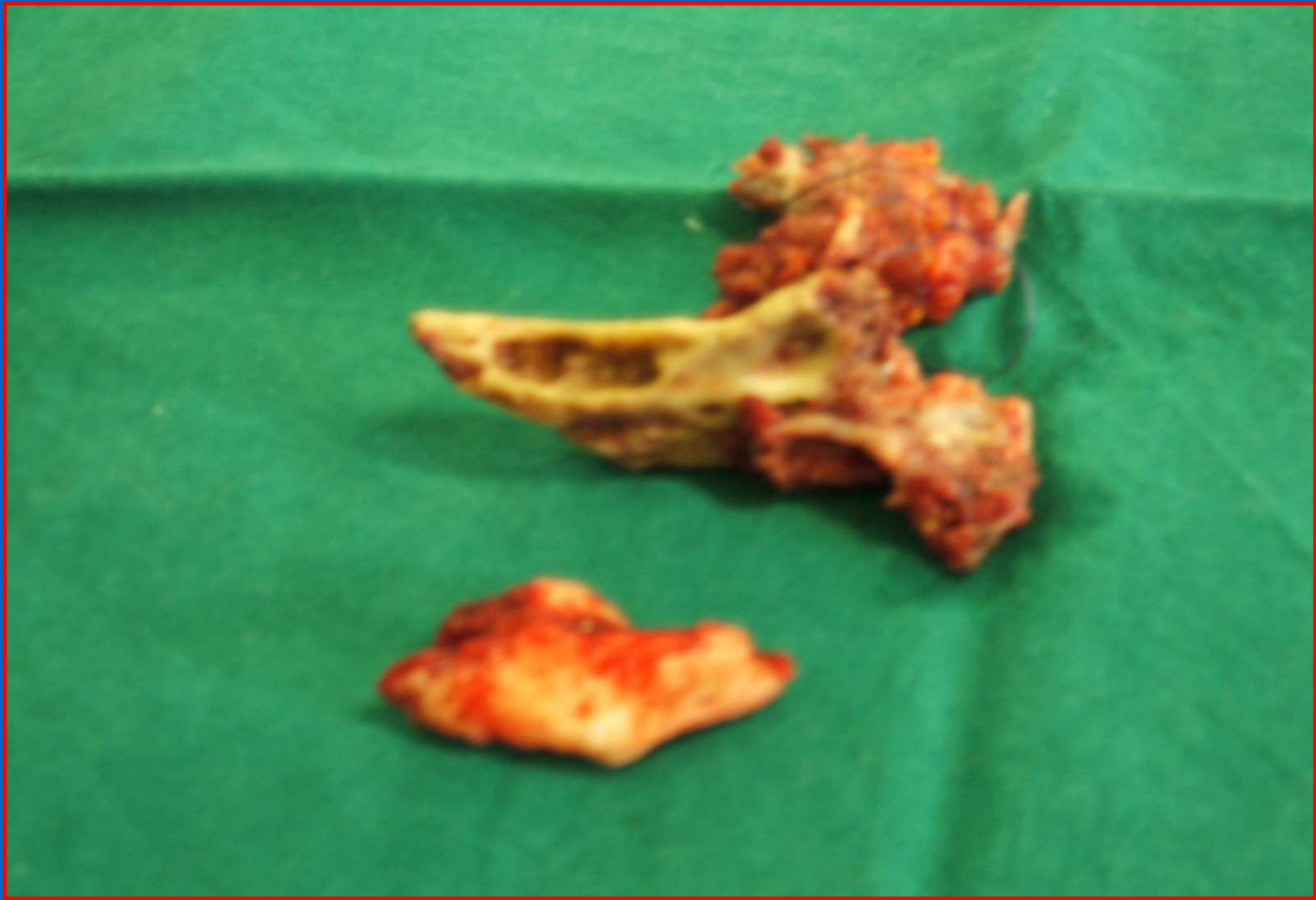
-
-
-



-
-
-
-
-
-
-
-

-
-
-

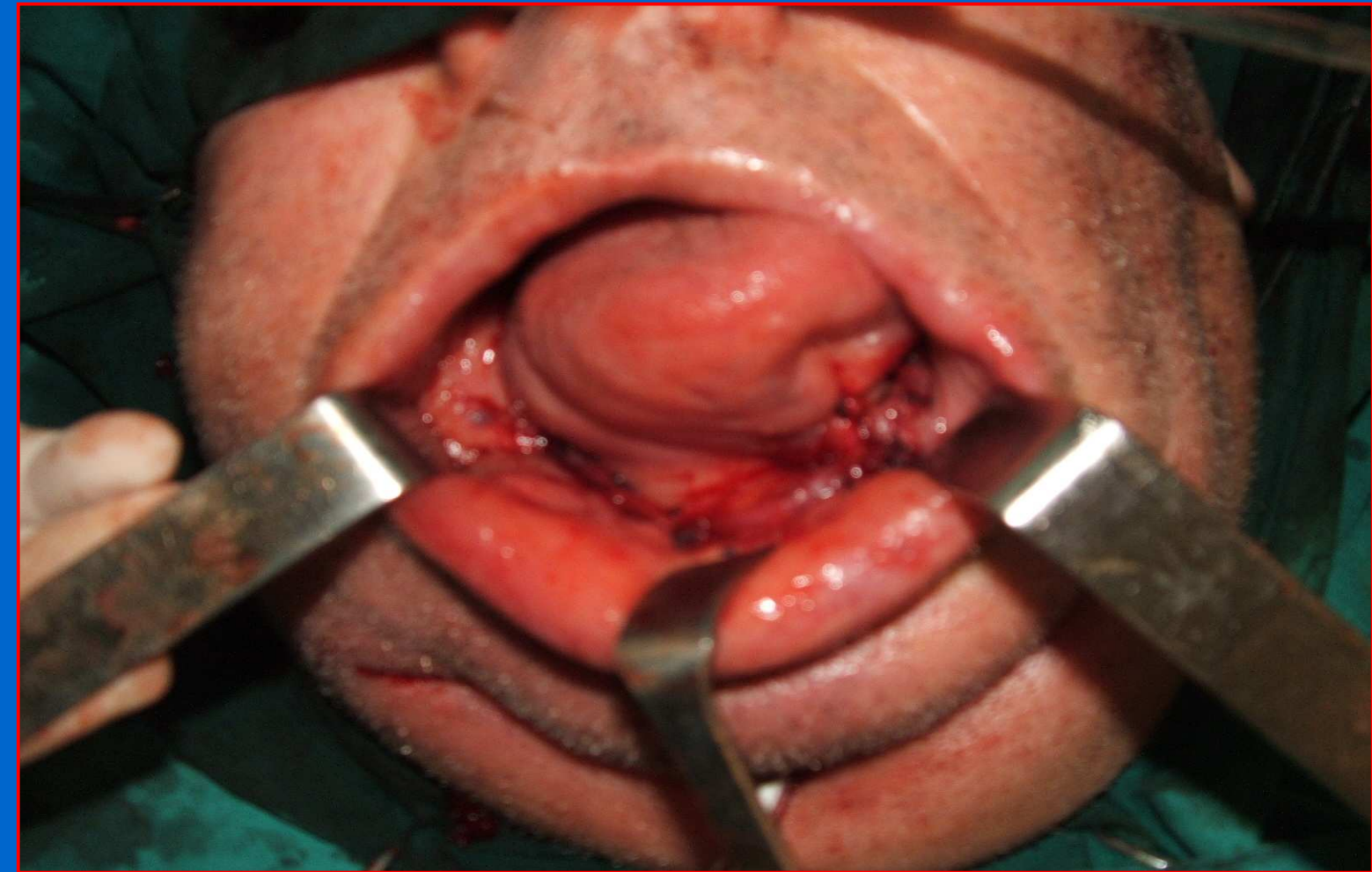
[Redacted text block]



[Redacted text block]

-
-
-
-
-
-
-
-

-
-
-



-
-
-
-
-
-
-
-