



TRATTAMENTO DELLA ONJ: *Terapia chirurgica non estesa*

Giuseppe Colella

Dipartimento Universitario di Patologia della Testa e del Collo.
Seconda Università degli Studi di Napoli
giuseppe.colella@unina2.it

Poche luci, molte ombre

www.follmi.com



TERAPIA CHIRURGICA

- Indicazioni:
- Pazienti sintomatici
- Fratture patologiche mandibolari
- Aree di osso necrotico responsabili di infezioni non responsive ai colluttori ed alla terapia antibiotica

AAOMS POSITION PAPER— 2009 UPDATE

Stage 3: these patients benefit from debridement, including resection, combined with antibiotic therapy, which might offer long-term palliation, with resolution of acute infection and pain.

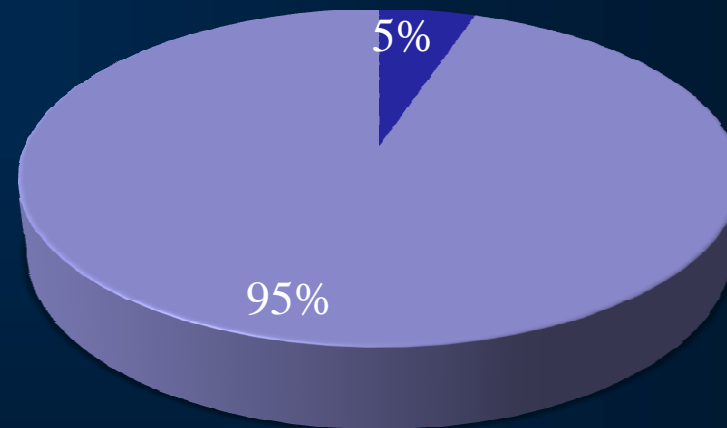
Regardless of the disease stage, mobile segments of bony sequestrum should be removed without exposing uninvolved bone. The extraction of symptomatic teeth within exposed, necrotic bone should be considered since it is unlikely that the extraction will exacerbate the established necrotic process.

CHIRURGIA NON ESTESA PRINCIPALE OPZIONE TERAPEUTICA

CASISTICA MULTICENTRICA

chirurgia estesa	18
chirurgia non estesa	331
terapia medica	226
nd	98
totale	673

■ chirurgia estesa ■ chirurgia non estesa



ISSUES

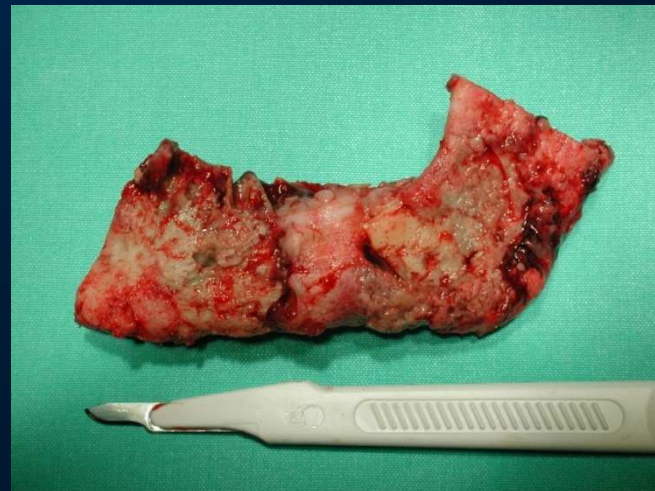
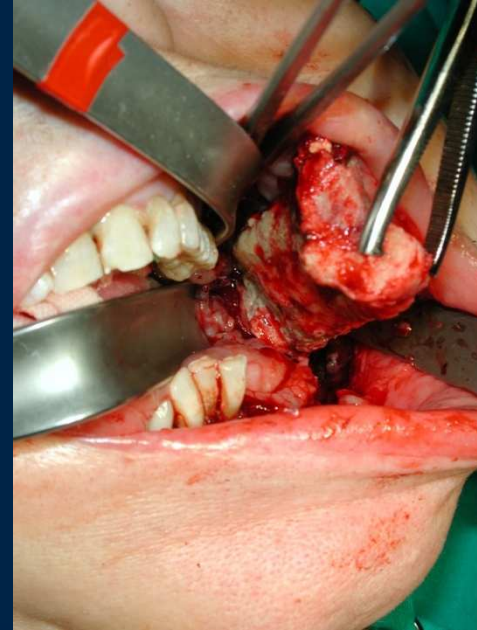- Terminologia
- Definizione del limite chirurgico
- Timing dell'intervento
- Terapie associate
- Protocolli terapeutici
- Valutazione dei risultati
- Istologia
- Conclusioni

Terminologia

CHIRURGIA ESTESA (RESETTIVA)

- Forme refrattarie-

- Resezione segmentale
- Resezione marginale

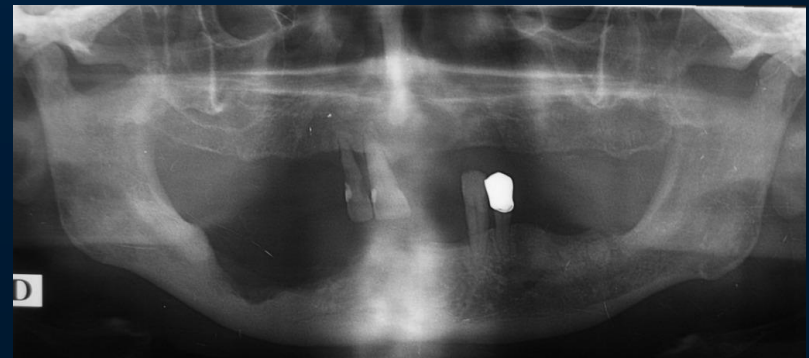
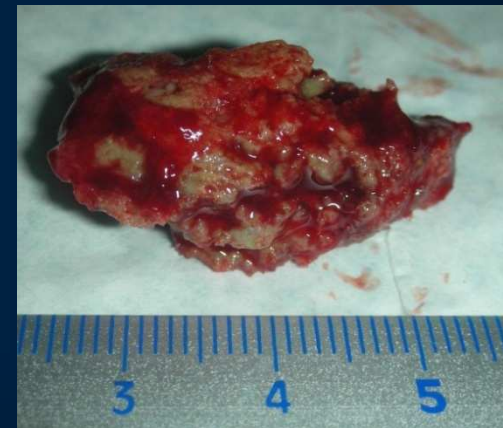
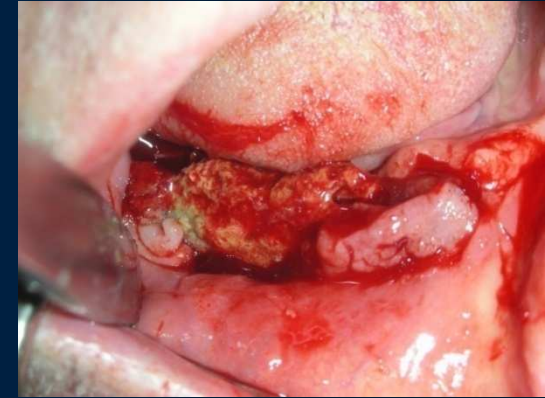
Terminologia

CHIRURGIA *NON* ESTESA

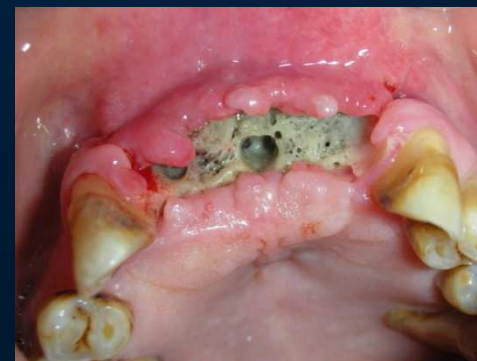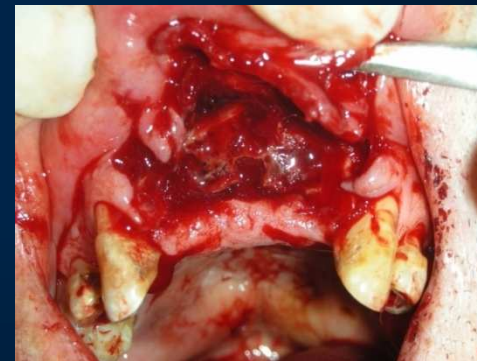
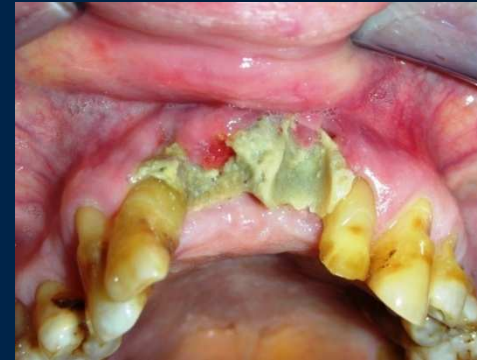(CONSERVATIVA)

- Curettage
- Debridement
- Sequestrectomia
- Corticotomia
- Osteoplastica
- *Resezione marginale !*



Definizione del limite chirurgico

- Limite “ non friabile”
- Fino ad osso vitale sanguinante
- Fino ad un punto presunto di riattivazione biologica



SPECT/TC

metilen-difosfonato (MDP) Tc-99m

Trifasica

- fase perfusionale

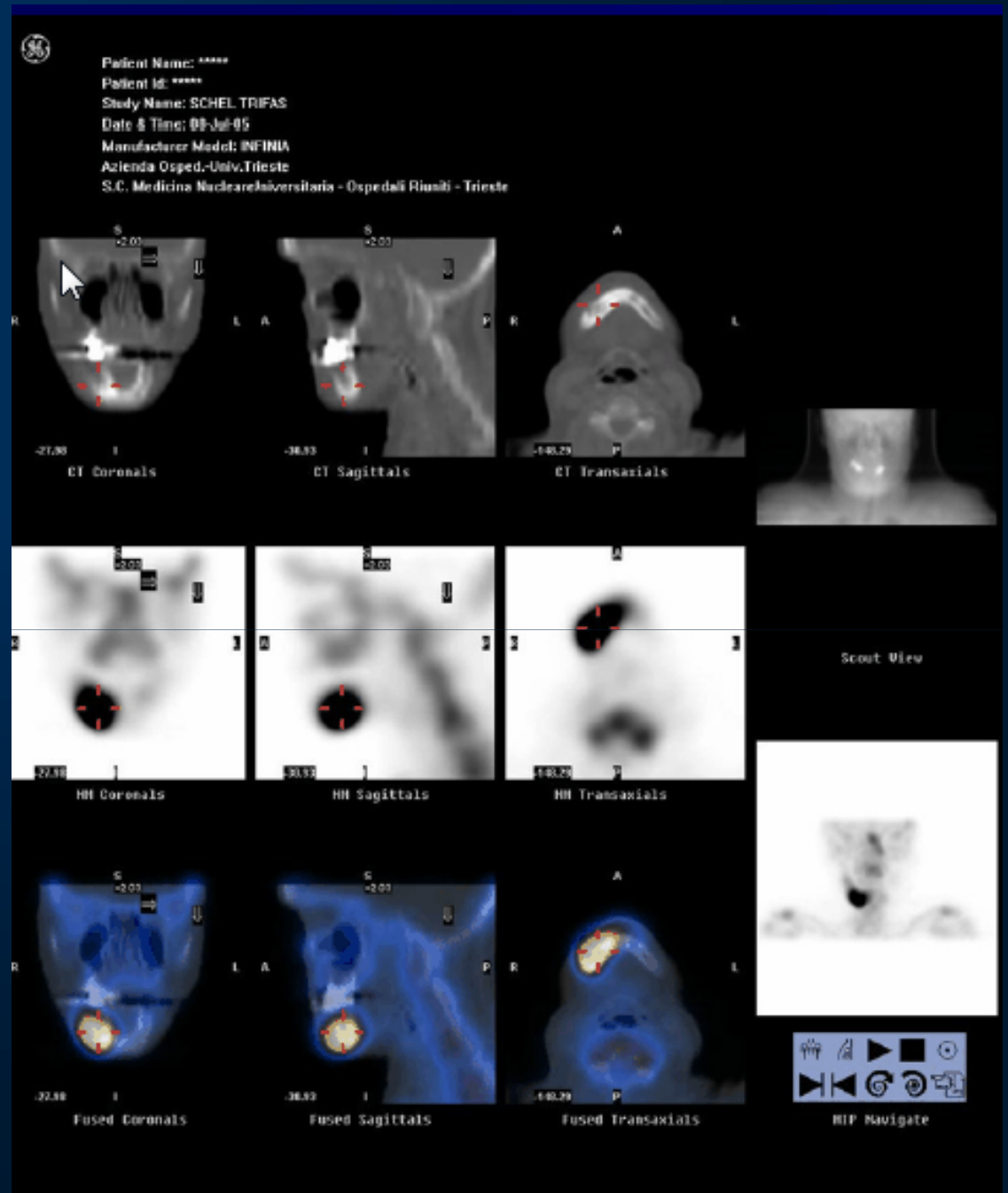
- fase vascolare

grado di infiammazione e/o infezione associata alla necrosi ossea;

- fase metabolica

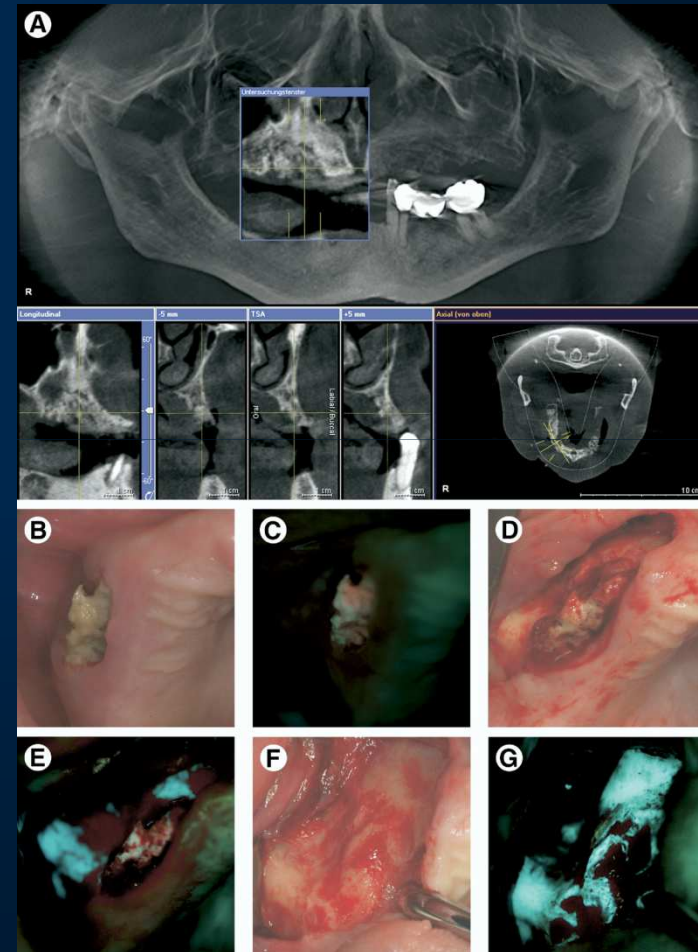
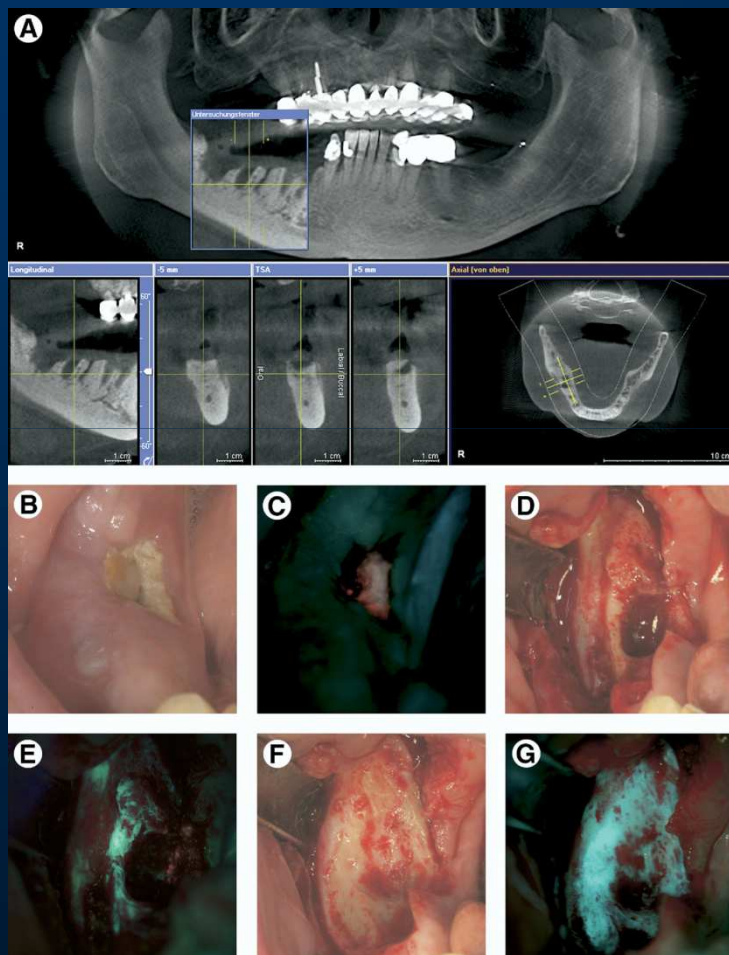
estensione della lesione necrotica

(ipocaptazione con attorno l'iperattività dovuta alla reazione osteoblastica all'aumentato turnover osseo) →



Prof. F.Dore, Trieste

Resezione ossea fluorescence-guided



Fleisher et al. Treatment of Bisphosphonate-Related Osteonecrosis of the Jaw. J Oral Maxillofac Surg 2008

Pautke et al. Fluorescence-Guided Bone Resection in BONJ. J Oral Maxillofac Surg 2009.

Timing dell'intervento

- Intervento precoce
- Attesa della formazione del sequestro

LETTERS TO THE EDITOR

J Oral Maxillofac Surg
66:831-833, 2008

EARLY SURGICAL APPROACH PREFERABLE TO MEDICAL THERAPY FOR BISPHOSPHONATE-RELATED OSTEONECROSIS OF THE JAWS

To the Editor.—The recently published practical guidelines for the management of osteonecrosis of the jaws (ONJ) in patients receiving bisphosphonate (BP) therapy reported that medical therapy associated with antimicrobial rinses could be suggested for patients with stage II ONJ (exposed necrotic bone associated with pain and infection), whereas surgical treatment should be reserved for those with stage III ONJ (exposed necrotic bone associated with pain and infection and pathological fracture, extraoral fistula, or osteolysis extending to the inferior border).¹ In addition, some authors have recommended medical therapy instead of surgical treatment for established BP-associated ONJ.^{2,3}

Wide-spectrum antibiotic treatment (eg, amoxicillin 2g/day in combination with metronidazole 500 mg twice a day for 15 days³) is of great value in the immediate management of the infectious process. In our experience, it is possible to observe a resolution of the symptoms for a period usually not exceeding 4 weeks. After that, a new cycle of antibiotic treatment becomes necessary when symptoms return. Interestingly, subsequent recurrences are progressively worse, and the symptom-free period becomes increasingly shorter, with the result that almost antibiotic treatment becomes necessary. Many cancer patients who undergo chemotherapy and are debilitated by the malignancy cannot bear the side effects of prolonged (and sometimes permanent) therapeutic antibiotic schemes.⁴ In addition, many of these patients demonstrate an uncontrolled progression of BP-related ONJ, characterized by such severe complications

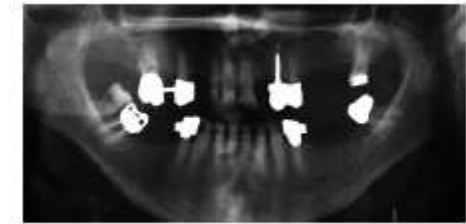

FIGURE 2. Panoramic radiograph showing no bone lesion at this stage, March 2006.

as pathological bone fracture and maxillary sinus and orbital involvement.

In light of these considerations, we report a 76-year-old woman who was diagnosed with breast cancer in 2000 and subsequently underwent several cycles of intravenous BP therapy (pamidronate for 4 months and zoledronic acid for 14 months, for a total of 18 months). In March 2006, she was referred by her dentist for an asymptomatic exposed necrotic avascular bone lesion localized on the left posterior mandibular segment, classified as stage I ONJ (Fig 1). This lesion was not visible on panoramic radiograph (Fig 2). No dental extractions had been performed in that area in the previous 3 years.

In accordance with international guidelines, the patient was treated with antimicrobial rinses for 2 months. Once the patient reported pain and local signs of infection (stage II), a 2-week course of antibiotics (oral amoxicillin associ-

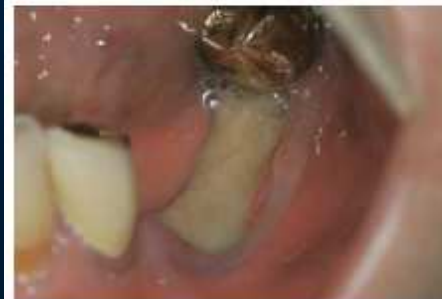

FIGURE 1. Exposed avascular necrotic bone area (stage I).

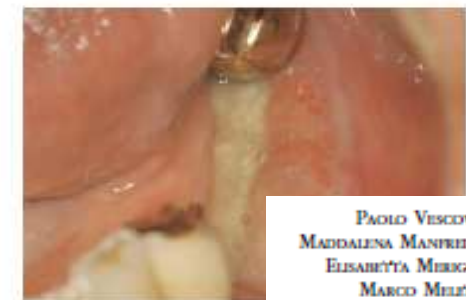

FIGURE 3. Mandibular abscess abscess (stage II).

PAOLO VESCOVI
MADDALENA MANFREDI
ELISABETTA MIBRGO
MARCO MELZI
Parma, Italy

Terapie associate

- Antibiotici
- HBO
 - (*Ruggiero 2004, Migliorati 2005, Bamias 2005*)
 - (*Chhoeu AH et al, J Oral Maxillofac Surg 2006*)
 - (*Freiberger JJ et al J Oral Maxillofac Surg 2006*)
 - (*Ma'Ann J et al AAOMS 2007*)
 - (*Magopulos C et al Am J Otolaryngol Head Neck 2007*)
- Ozono
 - (*Agrillo A. et al J Craniofacial Surg 2006*)
- Laser
 - (*Vescovi P et al J Oral Maxillofac Surg 2006*)
 - (*Vescovi P et al British J Oral Maxillofacial Surg 45 2007*)
 - (*Alons K et al Oral Surg Oral Med Oral Pathol Oral Radiol Endod 2009*)
- PRP
 - (*Curi MM et al J Oral Maxillofac Surg 2007*)

Protocolli terapeutici

- Drug holiday
- CTX-guided
- Terapia antibiotica
- Terapie associate
- Combinazione di terapie
- SU BASE EMPIRICA E NON EVIDENCE BASED



Osteonecrosis of the jaws due to bisphosphonate use. A review of 60 cases and treatment proposals

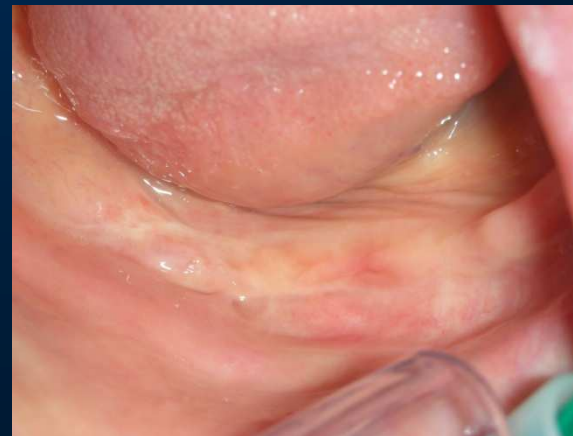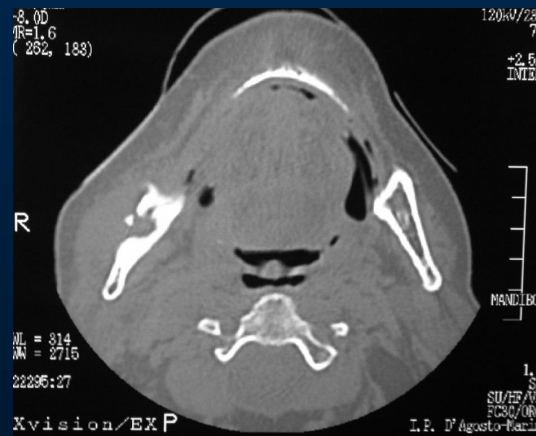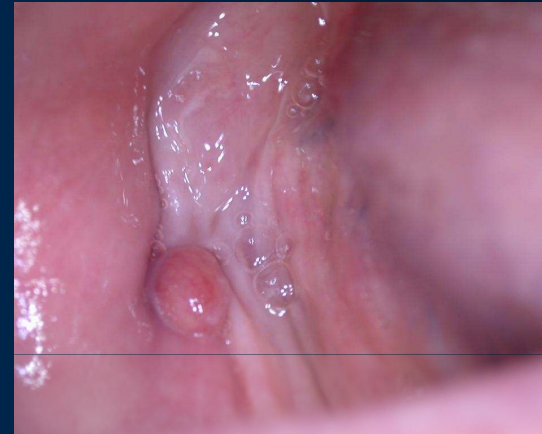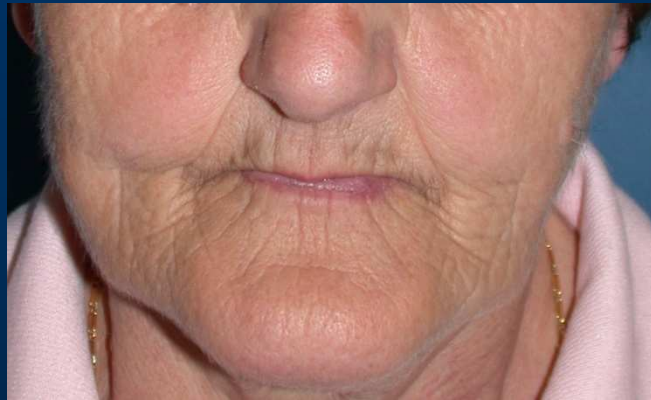Christos Magopoulos, DDS^{a,*}, Georgios Karakinaris, DDS^a, Zisis Telioudis, DDS^b,

1. Cessation of bisphosphonate therapy more than 6 months, HBO therapy, surgery, antibiotics (4 patients);
2. Cessation of bisphosphonate therapy more than 6 months, surgery, antibiotics (3 patients);
3. Cessation of bisphosphonate therapy less than 6 months, surgery, antibiotics (2 patients);
4. HBO therapy, surgery, antibiotics (6 patients);
5. Surgery, antibiotics (10 patients);
6. Cessation of bisphosphonate therapy, antibiotics, surveillance (24 patients);
7. Antibiotics, surveillance (11 patients)

Risultati

- IMPREDICIBILI
- Valutazione estremamente complessa per
 - Patologia di base e BPH usato
 - Tipo di chirurgia conservativa
 - Ampia variabilità dei protocolli terapeutici
 - Correlazione agli stadi (ampiezza stadio 2)
 - Definizione di risultato

BRONJ in osteoporosi



Valutazione dei risultati

- Estremamente complessa per
 - Patologia di base e BPH usato
 - Tipo di chirurgia conservativa
 - Ampia variabilità dei protocolli terapeutici
 - Correlazione agli stadi (ampiezza stadio II)
 - Definizione di risultato
 - *SEDE?*
 - *TEMPO?*

RISULTATI

LIVELLI DI SUCCESSO CLINICO		
Livello b	Scomparsa del dolore	Remissione dei sintomi
	Remissione dei segni clinici	Regressione delle fistole / fistole non produttive
Livello a	Remissione delle deiscenze mucose	Copertura completa delle esposizioni ossee

Level –a- transition from a higher stage to stage 0,
Level –b- transition from a higher to a lower stages.
Maintenance of results for over at least three months

RISULTATI

STAGE	FINDINGS
III	Persistence of bone exposure, pain, inflammation, secondary infections, cutaneous fistulas and pathological fractures
II	Presence of bone exposure with pain, infection and swelling in the lesion's area. Disappearance of cutaneous fistulas
I	Presence of bone exposure , regression of infection's signs, regression of symptoms
0	Complete mucosal healing, absence of symptoms, absence of infections signs,

ISTOLOGIA DEI MARGINI E DEL FONDO!

Autore	casi	Tumore
Bedogni (1)	2	Ca mammella Ca tiroide
Longobardi (2)	2	nd
Carlson (3)	3	Mieloma multiplo
Fleisher (4)	1	SCC
Colella (5)	3	Mieloma multiplo

(1) :Bone 41 (2007) 942–945

(2): J Craniofac Surg 18 (2006) 1012-1017

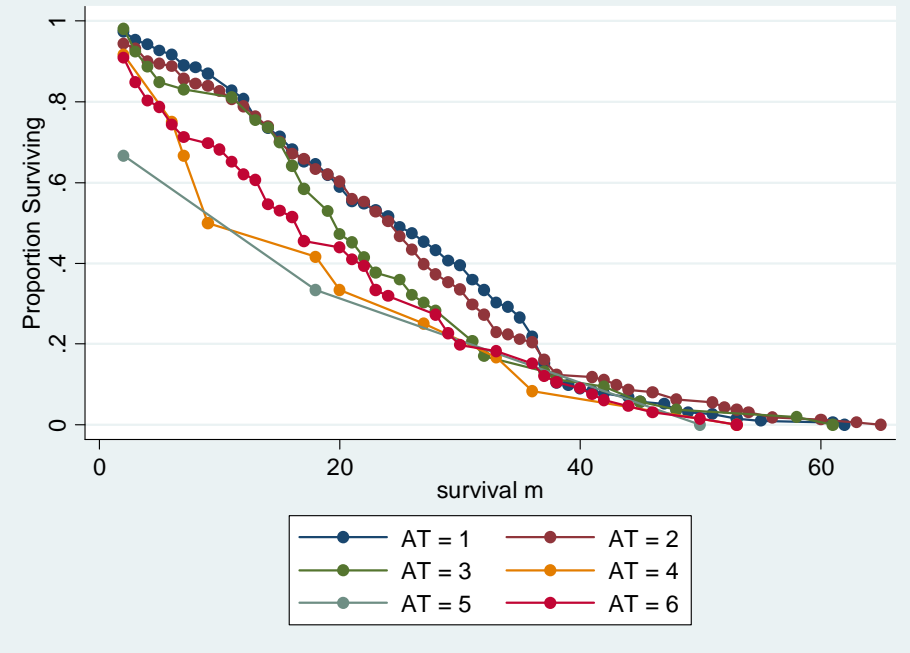
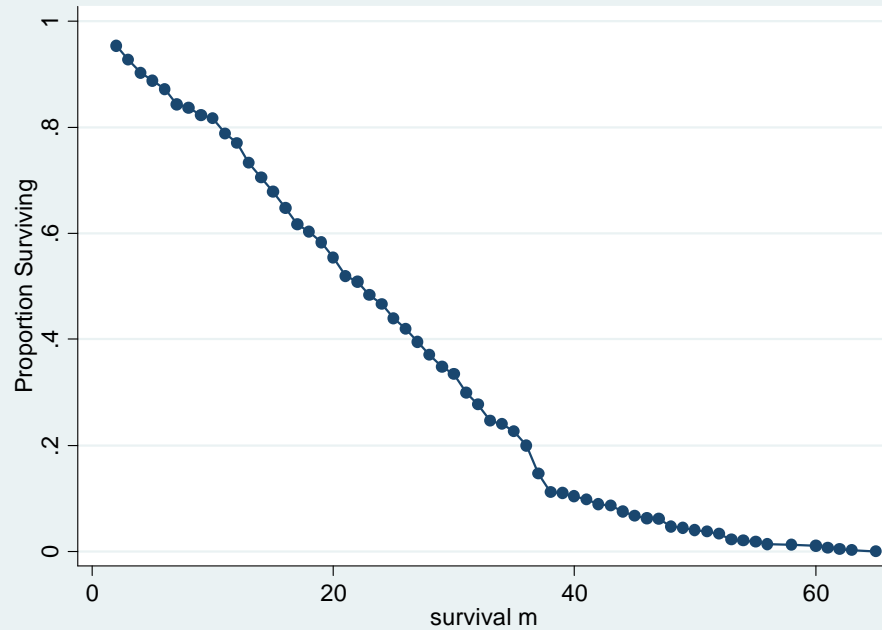
(3): *J Oral Maxillofac Surg* 67:85-95, 2009, Suppl 1

(4): *J Oral Maxillofac Surg* 66:2646-2653, 2008

(5): unpublished data

LAST BUT NOT LEAST:

CONDIZIONI GENERALI DEL PAZIENTE ASPETTATIVA DI VITA



Sopravvivenza globale

Sopravvivenza per
Neoplasia

1 = mieloma

2 = mammella

3 = Prostata

4 = Polmone

5 = Colon

6 = Altre



TRATTAMENTO DELLA ONJ:

Per una chirurgia sostenibile

Giuseppe Colella

Dipartimento Universitario di Patologia della Testa e del Collo.
Seconda Università degli Studi di Napoli
giuseppe.colella@unina2.it